



Multiple ureteral stent placement reduces restenosis after incision and dilatation for ureteral stenosis

Teruaki Sugino^{1,2}, Shuzo Hamamoto¹, Masahiko Isogai¹, Yutaro Tanaka¹, Rei Unno¹, Kazumi Taguchi¹, Ryosuke Ando¹, Atsushi Okada¹, Tohru Mogami¹, Takahiro Yasui¹

1 Department of Nephro-urology, Nagoya City University Graduate School of Medical Sciences, Nagoya, Japan.

2 Department of Urology, JA Aichi Anjo Kosei Hospital, Anjo, Japan.

Introduction and Objectives

- Ureteral strictures (US) is one of the complications after ureteroscopy (URS). (Geavlete P et al. J Endourol: 2006.)
- The aim of this study is to investigate the effectiveness of a method to place multiple ureteral stents after laser endoureterotomy (LE) and balloon dilatation (BD) for US.

Materials & Methods

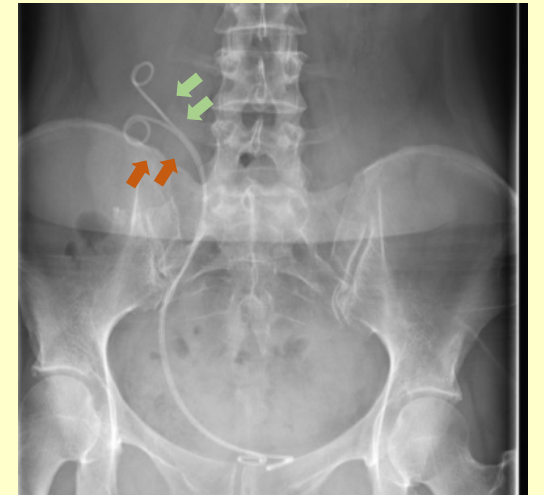
- 10 patients who underwent endoscopic surgery for US
- January 2016 to March 2019

< Surgery >

LE: Laser incision of the stricture site, including 5mm before and after, until the fat tissue outside the ureter was visible.

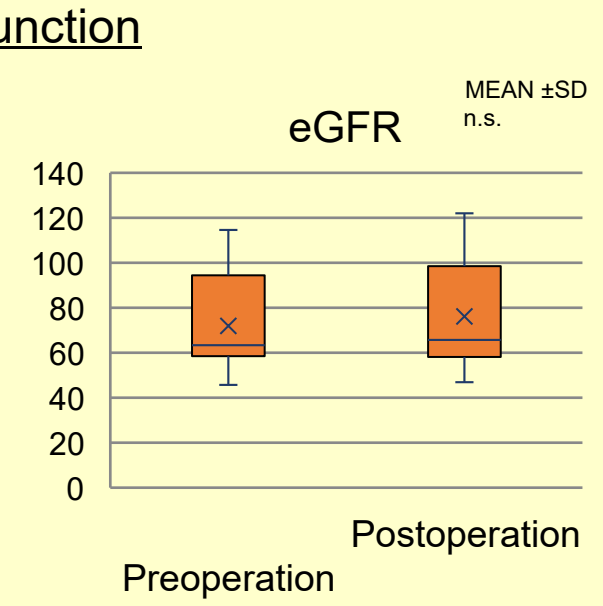
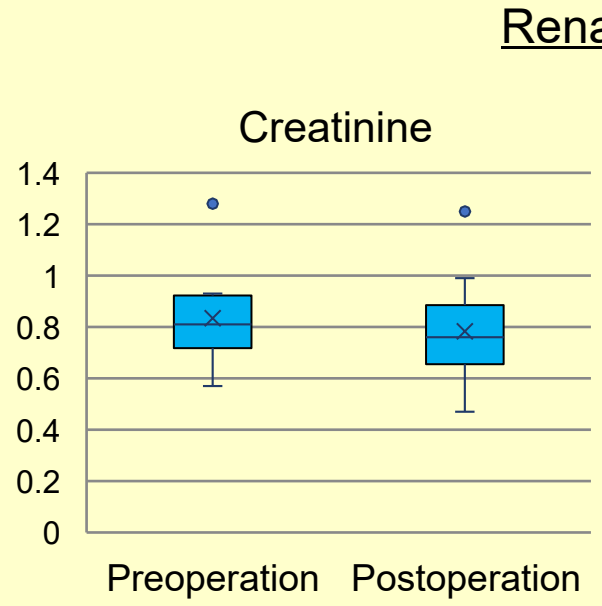
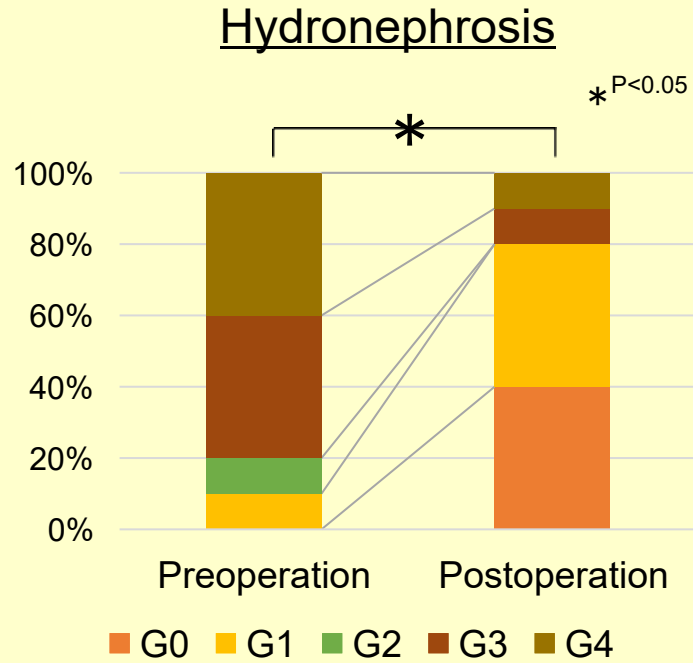
BD: Dilation with a balloon up to 15 Fr

Stent placement: two 4.7 Fr ureteral stents



Results

- Surgical time: 111.2 ± 21.5 minutes
- Hospital stay: 4.1 ± 0.5 days



- ◆ Hydronephrosis was improved in 9 patients (90%) 3 months after the surgery.
- ◆ Renal function tended to improve (P=0.11).

Conclusions Placement of multiple ureteral stents after surgery for ureteral stenosis was effective.