



ARMY MEDICINE
One Team... One Purpose
Conserving the Fighting Strength Since 1775



MADIGAN
ARMY MEDICAL CENTER

Automated Flow Cytometry Urine Analysis: Reassessing the Gold Standard of Microscopic Hematuria

**Alexandria M. Hertz MD, Mark I.
Anderson MD, Timothy C. Brand
MD**

No disclosures
Views my own, not that of the DoD

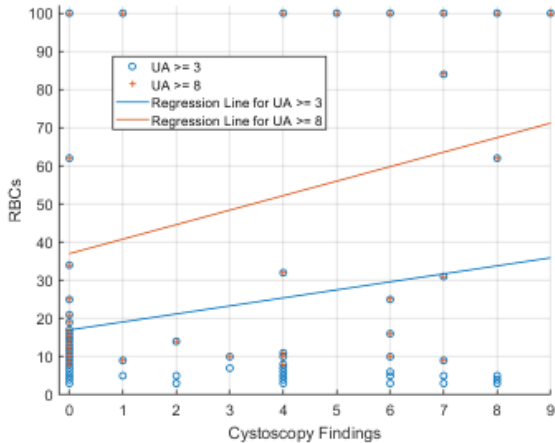
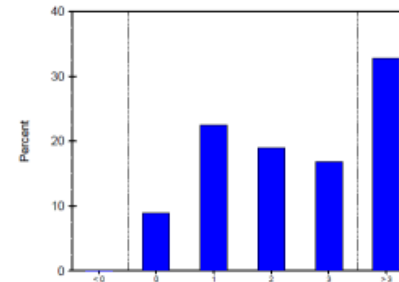


Arkray Aution AU-4050

Results Distribution

Interval	Percent	Count
< 0	0.0	0
0	8.9	36
1	22.5	91
2	19.0	77
3	16.8	68
> 3	32.8	133

Reference Interval Histogram



Cystoscopy

- Findings:** 0-Normal
 1- Bladder tumor 2- Stones 3- Diverticulum 4- BPH
 5-Radiation Changes 6- Urethral stricture
 7- Declined Cysto 8- Cystitis 9- AVM

