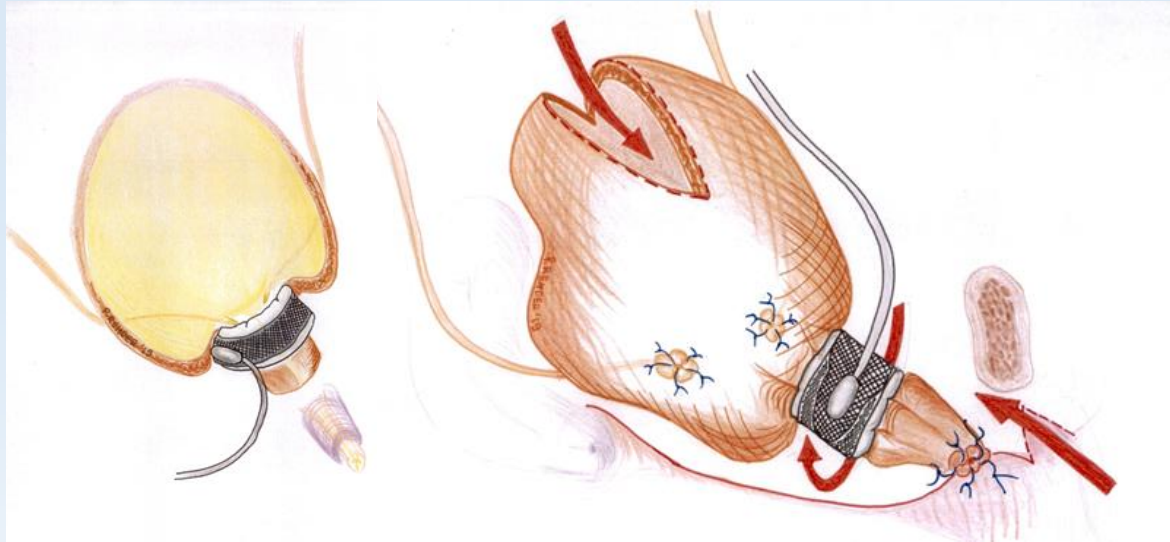


What to do when the urethra is absent?

1. Wrapping bladder outlet into tube
2. Placing AUS with circumtrigonal cuff



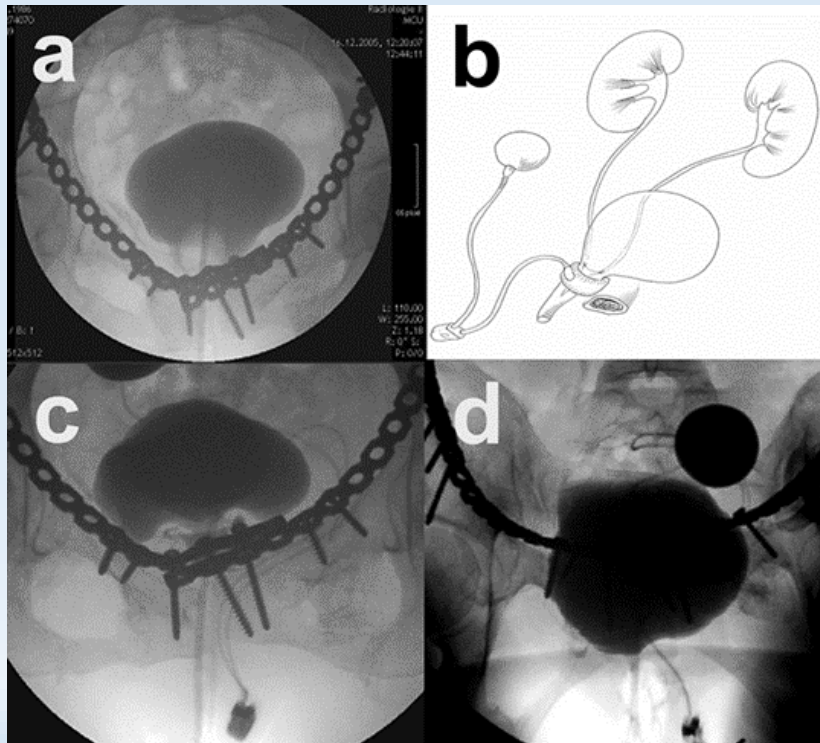
©Peter Rehder

Mean follow-up 7 years

- n=5: 4♀ 1♂
- average age at surgery 33 years
- cuff sizes used in cm
 - 4.5; 6.5; 2x 8 (all ♀)
 - 10 (♂)
- activation 6-8 weeks post-surgery
- post-activation all continent
- no intra-operative complication
- ♂ patient: AUS infection + explant

After trigonal tube configuration...

1. Two patients successful pregnancies
2. Place cuff around virgin tissues



Challenging techniques:

Wrapping of bladder outlet, proximal to the bladder neck to configure a neo-urethra

- promising in select cases of total urinary incontinence with an absent functional urethra
- especially in young females.

Circumtrigonal cuff placement seems useful alternative in young ♀ patients that lost urethral function

©Peter Rehder