



The classification and management for extramammary Paget's disease.

MP29-01

Haijun Yao, Dachao Zheng, Minkai Xie, Yueqing Jiang, Zhong Wang

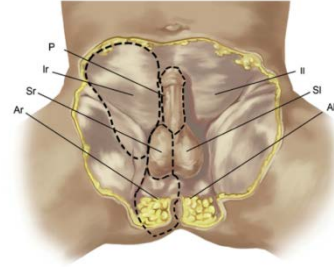
Dept. of Urology, Shanghai Ninth People's Hospital, Shanghai JiaoTong University School of Medicine, China

1.Introduction and Objective

Extramammary Paget's disease (EMPD) is a rare cancer which involves the skin and apocrine glands. It involves perianal region, scrotum, penis, and axilla. The primary disease originates from intraepidermal cells and secondary originates from underlying neoplasm. Up to now, no clear guidelines have been established for the diagnosis, treatment, and follow-up. Surgical excision is the standard treatment, but results in mutilating procedures in patients with the advanced or recurrent disease. This study aimed to evaluate the classification and choose the treatment strategy of EMPD.

2.Materials and Methods

All 192 cases of EMPD, diagnosed between 2003 and 2017, were selected from Shanghai 9th People's Hospital, Shanghai JiaoTong University, School of Medicine. All cases of biopsy-proven penoscrotal EMPD were included in this retrospective analysis. Factors reported to be associated with survival such as positive surgical margins, local recurrence, distant metastasis, lymph node (LN) metastasis, and primary tumor status were evaluated using the log-rank test. The surgical resection with clear margins is considered to be the standard of care and provides good outcomes. However, if surgery is not feasible other treatment options like imiquimod 5% or 5-Fu topical cream may be offered.



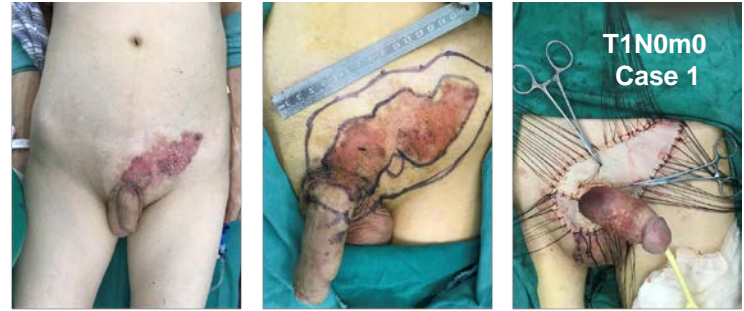
the PISA classification
The defects were categorized according to their anatomic location: right (r) and left (l)

- penis (P),
- scrotum (Sr and SI),
- inguinal area (Ir and II),
- perianal area (Ar and AI).

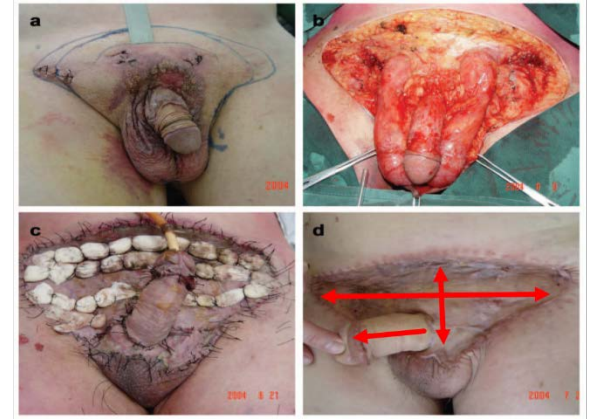
Ahn DK, et al. Urology, 2014, 84(5):1217-1222.

3.Results

We enrolled 192 EMPD patients, of whom 34 had remote metastases (10 had both distant and LN metastasis; 5, distant metastasis only; and 19, LN metastasis only) and the remaining 158 patients had no remote metastasis. Patients who had no remote metastasis and tolerable anesthesia were treated with surgical therapy (Wide local excision). Flaps or Graft were needed if there were massive defect after appropriate wide excision, primarily when the tumor was very extensive. According to the PISA method, we choose the strategy to reconstruct the penile and scrotum with flap or skin graft. Other treatment options like imiquimod 5% or 5-Fu topical cream may be offered. The size of the wound after radical resection is a significant challenge for reconstruction. Distant metastasis (M1), 2 or more LN metastases (N2), tumor thickness of over 4 mm or lymphovascular invasion showed worse survival (P < 0.01).



EMPD T1N0M0 (P+SI+II) WLE+STSG (15cm*10cm)



EMPD T1N0M0 (P+SI+Sr+II+Ir) WLE+STSG (30cm*20cm)

Age	Primary site by PISA Classification	
Average	68	penis 102
Range	50-85	scrotum(Sr and SI) 158
Sex		Inguinal area(Ir and II) 49
Male/Female	190 / 2	Perianal area(Ar and AI) 54
Classification by TNM (Invasion level)	Reconstruction method	
I	55(29%)	primary closure 55
II	103(53%)	local penile shaft 55
IIIa	2(1%)	scrotal flap 78
IIIb	17(9%)	split-thickness skin graft(STSG) 68
IV	15(8%)	anterolateral thigh perforator flap (ALTP) 7

4.Conclusion

Patients can be in the same stage, but the reconstruction method is different. Based on TNM classification and stage, the treatment strategy is more conducive to the prognosis of EMPD, and significantly improves the quality of life. And the PISA classification provides a simple way to specify the anatomic location and extent of a defect of the penoscrotal region, and permit more effective and straightforward reconstruction.

TNM	0	1	2
T	Tumor in situ	Tumor thickness ≤ 4mm AND no lymphovascular invasion	Tumor thickness > 4mm OR lymphovascular invasion
N	No LN metastasis	1 LN metastasis	2 or more LN metastasis
M	No distant or LN metastasis beyond regional LN basin	Distant organ metastasis or LN metastasis beyond regional LN basin	(-)
staging	T	N	M
I	1	0	0
II	2		
III a	Any	1	
III b		2	
IV		Any	1

stage I, T₁N₀M₀;
stage II, T₂N₀M₀;
stage IIIa, anyTN₁M₀;
stage IIIb, anyTN₂M₀;
stage IV, anyT_{any}NM₁

K. Ohara, et al. J Dermatol Sci. 2016, 83 (3):234-9

If you need any further assistance, please contact: Haijun Yao
Email: dryaohj@163.com